



Chronic Marijuana Use is Associated with Micro-Structural Alterations in the Human Brain



Rachael M.K. Gonzales, B.A.¹, George King, Ph.D.²,

Helenna Nakama, M.D.², Thomas Ernst, Ph.D.²; and Linda Chang, M.D.²

¹Clinical Research-Neuroscience Graduate Program, University of Hawaii at Manoa

²Department of Medicine, John A. Burns School of Medicine, University of Hawaii at Manoa

Introduction

➤ Marijuana (THC) is the most commonly used illicit drug in the United States¹ and chronic use has been associated with memory deficits².

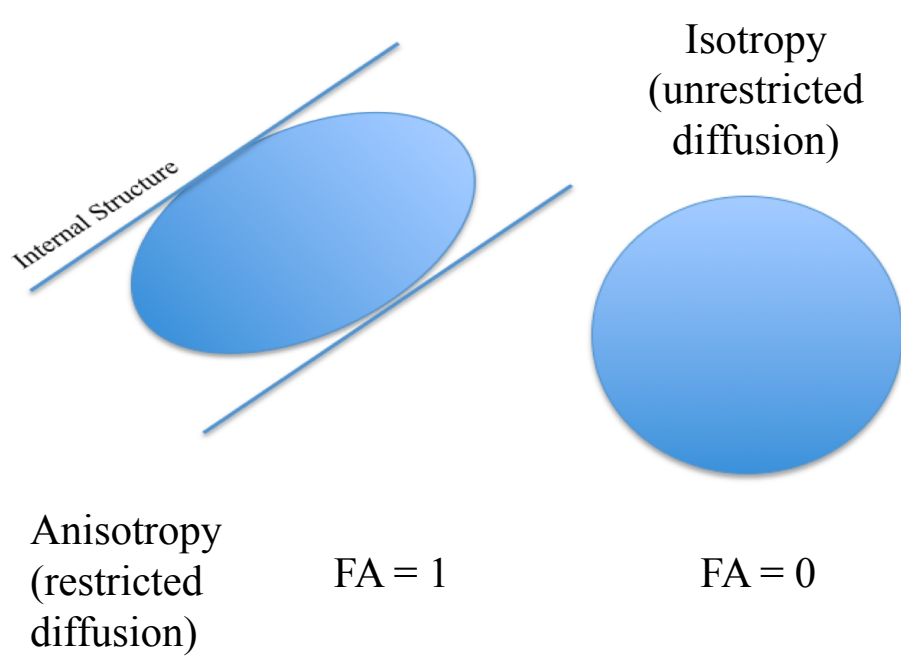
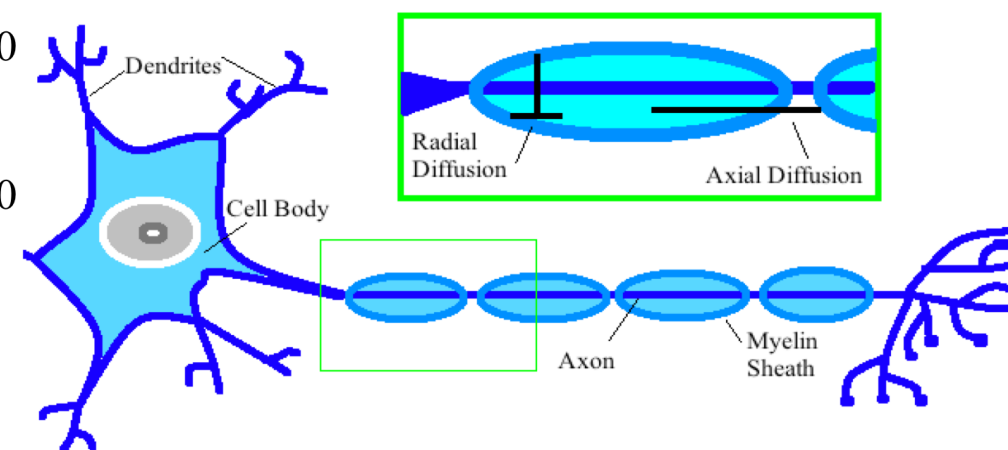
➤ Diffusion tensor imaging (DTI) uses water movement to detect micro-structural changes in the brain.

- DTI studies have produced conflicting results as to whether or not THC use is associated with structural alterations³⁻⁶.
- One reason for inconsistencies may be the use of different DTI analysis protocols, such as TBSS, FACT, and manual region of interest (ROI) placement.
- The use of Large Deformation Diffeomorphic Metric Mapping (LDDMM)⁸ minimizes intra- and inter-rater variability, can be used for single subject analysis, and improves the accuracy of ROI placement.

➤ HYPOTHESIS: Chronic adult marijuana users will show micro-structural alterations in regions related to language and working memory.

Study Characteristics

- Controls: n = 25
 - Mean age: 24.7 ± 1.4 years; 15 males and 10 females
- THC users: n = 25
 - Mean age: 26.1 ± 1.7 years; 15 males and 10 females
 - Mean age of first use: 15.9 ± 0.52 yrs
 - Mean daily cannabis use: 4.1 ± 1.2 g/day
 - Mean duration cannabis use: 10.3 ± 2.7 yrs



- Fractional Anisotropy (FA) measures organization or integrity of white matter fiber bundles. Statistically lower FA may reflect incoherence of fiber tracts.
- Apparent Diffusion Coefficient (ADC) measures the average motion of water molecules in brain tissue. Statistically lower ADC may reflect more compact axonal fibers.
- Axial Diffusivity (aDiff) measures water diffusion along the longitudinal axis. Statistically lower aDiff may reflect alterations to the axon.
- Radial Diffusivity (rDiff) measures water diffusion along the perpendicular axis. Statistically higher rDiff may reflect damage to the myelin.

Methods

➤ Subjects underwent a battery of neuropsychological tests measuring various cognitive domains (e.g. working memory).

- Auditory Verbal Learning Task (AVLT)
- Rey-Osterrieth Complex Figure (RCF)

➤ 3 T Siemens Trio Scanner (Erlangen, Germany)

- Axial spin-echo EPI DTI scans with full-brain coverage (12-diffusion-directions, 28 slices, 4.6mm slice, 0.46mm gap, TR/TE=3700/88ms, 128x128x28, b factor=(0,1000) s/mm²) were acquired.

➤ FA, ADC, aDiff, and rDiff were calculated using DtiStudio version 3.0.1beta7.

- ROI analyses utilized LDDMM⁸.
- 65 bilateral regions were extracted, including subcortical, superficial white, and cortical gray matter regions.
- Data were analyzed using a 2-between (Drug Use & Gender) 1-within (Hemisphere) mixed model ANOVA.
- The regions presented in the results table were selected from the total set of significant data because of their reported involvement in language and working memory.

LDDMM Maps

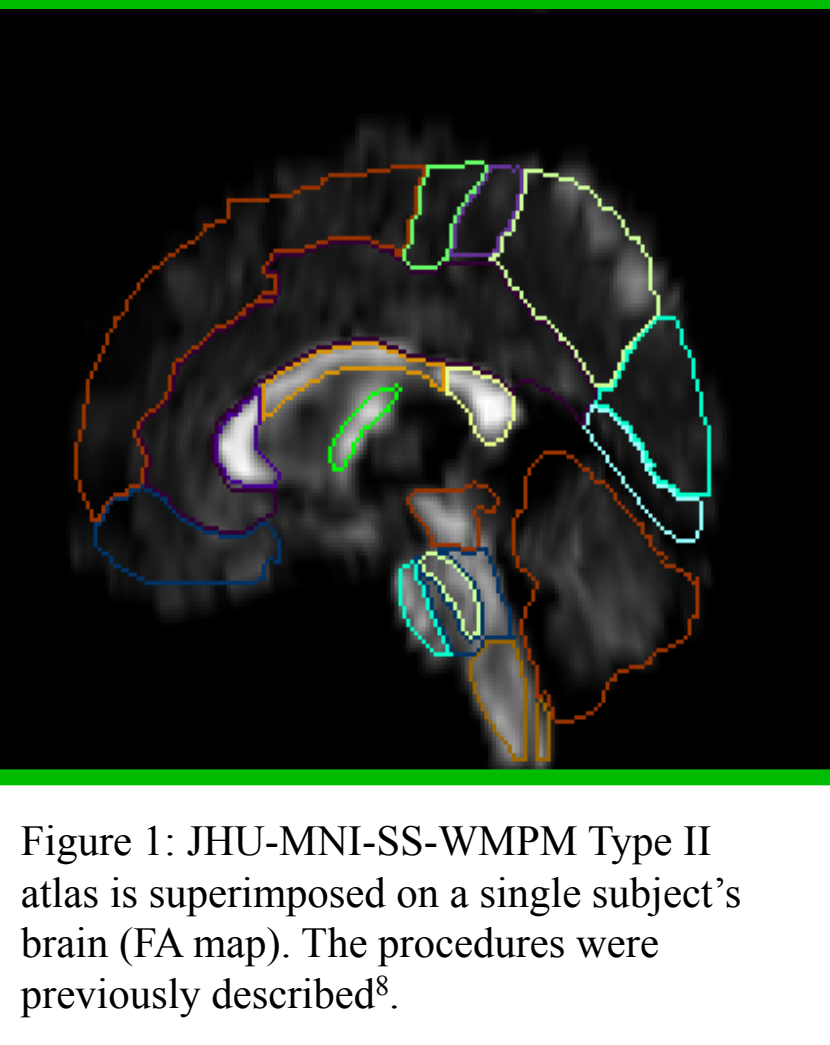
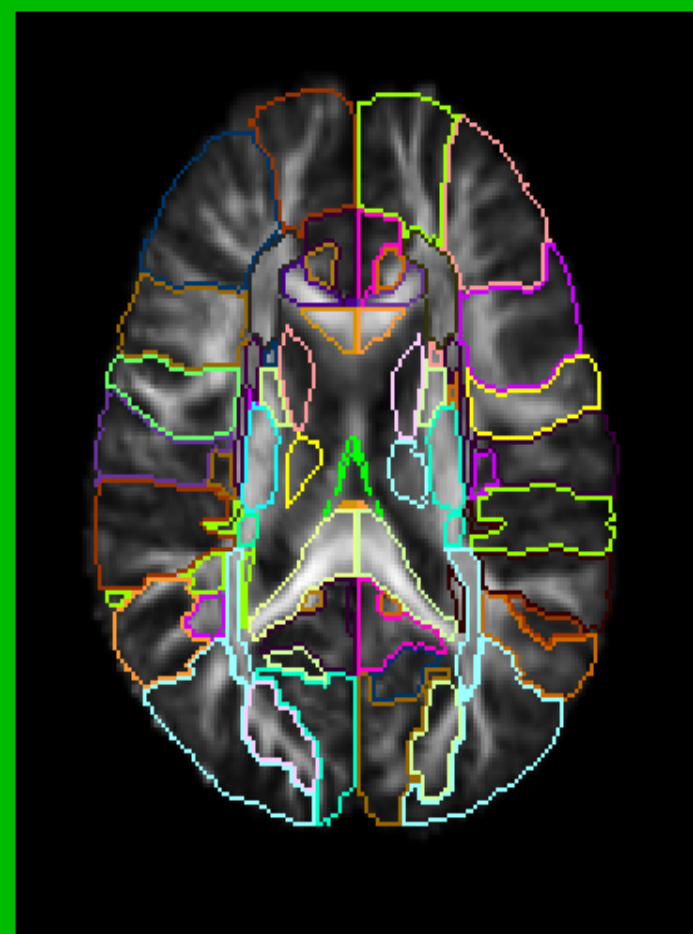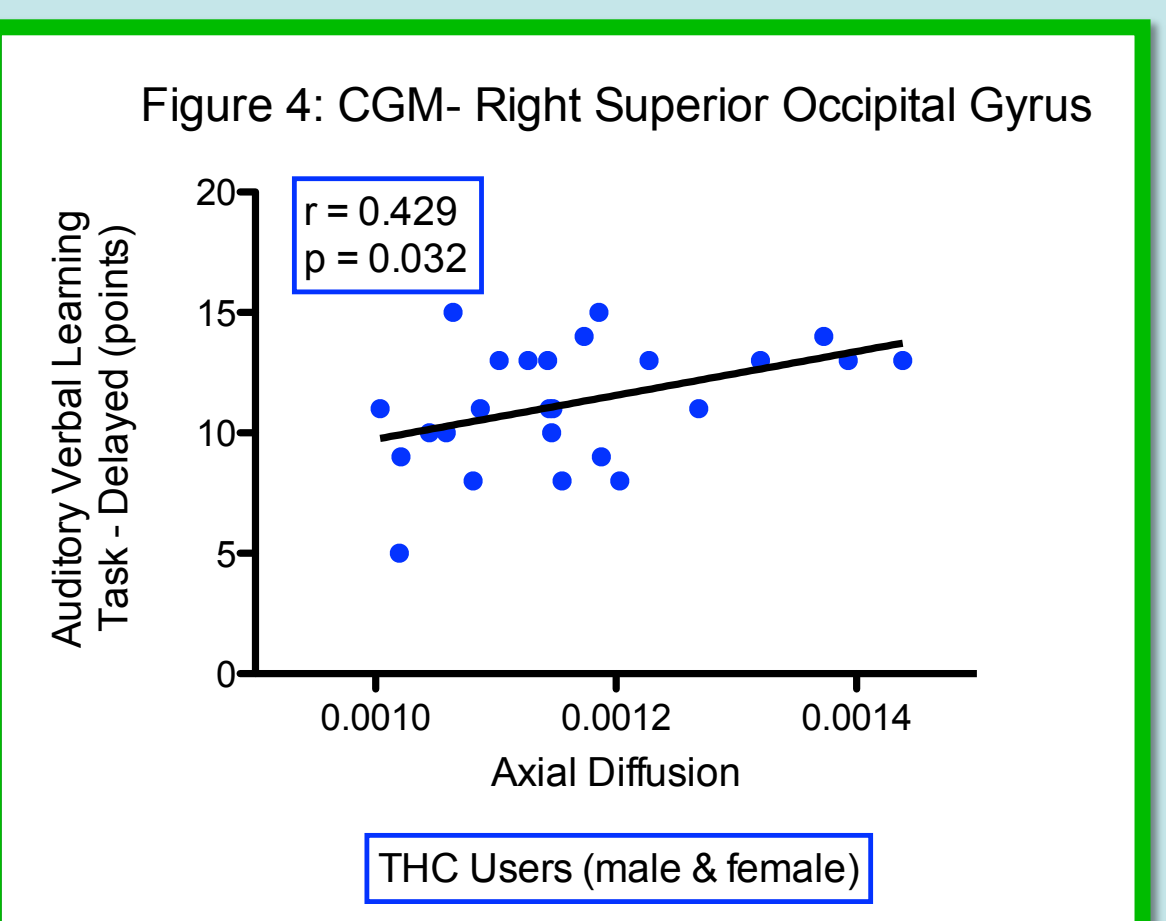
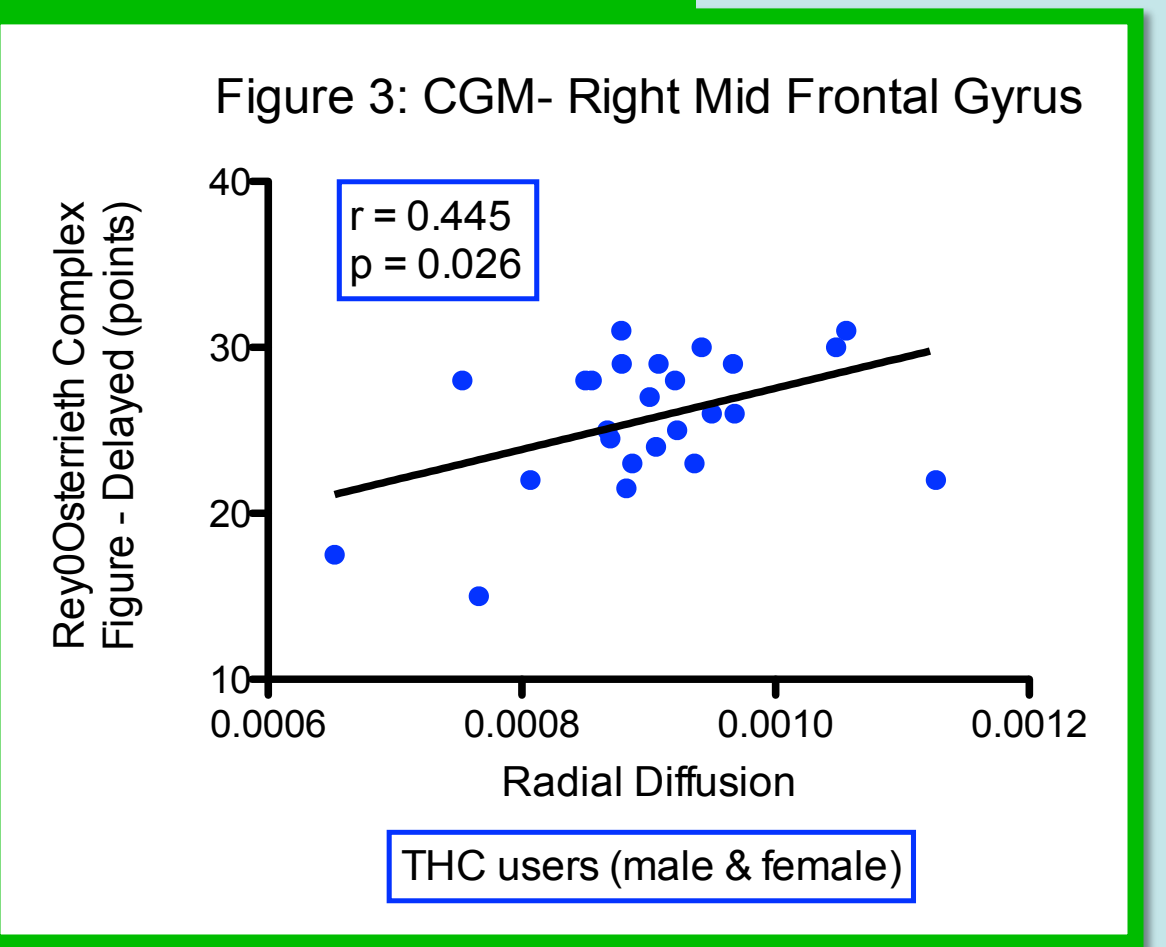


Figure 1: JHU-MNI-SS-WPMM Type II atlas is superimposed on a single subject's brain (FA map). The procedures were previously described⁸.

Results

Measure	Gyri	Cognitive Function	Group	Mean + Std. Error (*10 ⁻³)		F(1,44), p	Effect	Direction of Change	NPT Correlation, r (p < 0.05)
				FC	MC				
ADC	Angular	Language	FC	0.97	0.023	F = 11.41 p = 0.002	Group x Gender	MTHC < MC	RCF Delay MTHC r = 0.54
			MC	1.10	0.027				
			FTHC	1.02	0.023				
	Lateral Fronto-Orbital	Decision-Making	FC	0.87	0.012	F = 6.39 p = 0.02	Group	THC < C	None
			MC	0.91	0.098				
			FTHC	0.86	0.028				
Axial Diffusion	Angular	Language	FC	1.12	0.036	F = 8.98 p = 0.005	Group x Gender	MTHC < MC	RCF Delay MTHC r = 0.54; AVLT Delay MTHC r = 0.52
			MC	1.25	0.025				
			FTHC	1.16	0.025				
	Lateral Fronto-Orbital	Decision-making	FC	1.01	0.015	F = 7.30 p = 0.01	Group	THC < C	None
			MC	1.06	0.014				
			FTHC	0.99	0.033				
Superior Occipital	Visual working memory	FC	1.13	0.032	F = 6.38 p = 0.02	Group x Gender	MTHC < MC	AVLT Delay THC r = 0.43 Fig. 4	
		MC	1.23	0.034					
		FTHC	1.18	0.028					
Radial Diffusion	Angular	Language	FC	0.90	0.023	F = 12.28 p = 0.001	Group x Gender	MTHC < MC	RCF Delay MTHC r = 0.55
			MC	1.02	0.027				
			FTHC	0.95	0.023				
	Lateral Fronto-Orbital	Decision-making	FC	0.78	0.012	F = 7.65 p = 0.008	Group	THC < C	None
			MC	0.83	0.010				
			FTHC	0.77	0.028				
Middle Frontal	Working memory storage	FC	0.92	0.014	F = 6.03 p = 0.02	Group	THC < C	RCF Delay THC r = 0.45 Fig. 3	
		MC	0.99	0.011					
		FTHC	0.90	0.028					
Superior Occipital	Visual Working Memory	FC	0.89	0.033	F = 5.95 p = 0.02	Group x Gender	MTHC < MC	AVLT Delay THC r = 0.44	
		MC	0.93	0.023					
		FTHC	1.01	0.027					

Correlations



Discussion

- In our current study of young adults with a history of chronic marijuana use, we found micro-structural abnormalities, with lower diffusion in many regions, including those associated with language and working memory as hypothesized. Lower ADC, axial and radial diffusivities may suggest more compact axonal fibers, resulting from altered neural development.
- Interestingly, our data suggests that brain regions associated with visual working memory and attention may be more susceptible to alterations in male THC users but not female THC users. However, the sample size is still small in our group of female subjects.
- The micro-structure abnormalities in these regions also correlated with deficits in visual and verbal memory tasks, both required for working memory and attention.
- The brain regions associated with working memory have been shown to have cannabinoid (CB1) receptors present^{9,10}, the main site of action of THC¹¹. Therefore, these micro-structural abnormalities in our marijuana users are consistent with the molecular action of this drug's effect on the brain.

Future Tasks

- Calculation of intra- and inter-observer reliability
- Evaluation of more regions
- Increase sample size
- Comparison to adolescent marijuana users
- Design a longitudinal study to further investigate the effects of THC on neurodevelopment

Take Home Message

- Chronic marijuana use is associated with alterations in diffusion within the frontal, parietal, and occipital lobes which may reflect changes in axonal integrity.

References

1. SAMHSA – U.S. Dept of Health & Human Services – Office of Applied Studies, www.oas.samhsa.gov/marijuana
2. Pope HG Jr, Gruber AJ, Hudson JI, et al. (2001) Neuropsychological performance in long-term cannabis use. *Arch Gen Psychiatry*. 58: 909-15.
3. Ashtari M, Cervellione K, Cotton, et al. (2009) Diffusion abnormalities in adolescents and young adults with a history of heavy cannabis use. *Journal of Psychiatric Research*. 43:189-204
4. Arnone D, Barrick TR, Chengappa S, et al. (2008) Corpus callosum damage in heavy marijuana use: Preliminary evidence from diffusion tensor tractography and tract-based spatial statistics. *NeuroImage*. 41: 1067-1074.
5. DeLisi LE, Bertisch HC, Szule KU, et al. (2006) A preliminary DTI study showing no brain structural change associated with adolescent cannabis use. *Harm Reduction Journal*. 3: 17.
6. Gruber SA and Yurgelun-Todd DA (2005) Neuroimaging of marijuana smokers during inhibitory processing: a pilot investigation. *Brain Res Cogn Brain Res*. 23: 107-18.
7. Jiang H, van Zijl PC, Kim J, et al. (2006) DtiStudio: resource program for diffusion tensor computation and fiber bundle tracking. *Comput Methods Programs Biomed*. 81:106-16.
8. Oishi K, Faria A, Jiang H, et al. (2009) Atlas-based whole brain white matter analysis using large deformation diffeomorphic metric mapping: application to normal elderly and Alzheimer's disease participants. *NeuroImage*. 46:486-99.
9. Herkenham M, Lynn AB, Little MD, et al. (1990) Cannabinoid receptors localization in the brain. *PNAS* 87: 1932-6.
10. Glass M, Dragunow M, and Faull RLM (1997) Cannabinoid receptors in the human brain: a detailed anatomical and quantitative autoradiographic study in fetal neonatal and adult human brain. *Neuroscience* 77: 299-318.
11. Freund TF, Katona I, and Piomelli D (2003) Role of endogenous cannabinoids in synaptic signaling. *Physiological Review*. 83: 1017-66.

Acknowledgements

- This study is jointly supported by National Institute of Neurological Disorders and Stroke and National Institute of Drug Abuse (U54 NS56883), National Center for Research Resources (G12RR003061 & P20RR11091), the Office of National Drug Control Policy, & the Queen's Medical Center). There are no conflicts of interest.
- Thank you to Drs. Susumu Mori and Kenichi Oishi for their guidance and support for MRI Studio Software.
- Thank you to Jeff Sadino for training our lab in using LDDMM, and Caroline Jiang for her statistical analysis support.
- Thank you to Drs. Chang and Ernst for allowing me to join their research team and for providing me with an education in the latest techniques and analyses in neuroscience and MR imaging. *Mahalo nui loa!*

Contact Information

Rachael M. K. Gonzales, rachaelg@hawaii.edu, (808) 545-8974 office
Neuroscience and MRI Research Group, www.hawaii.edu/mri
Queen's Medical Center, 1356 Lusitana Street, UH Tower 7th Floor
Honolulu, Hawaii 96813